


ROBERT L. FINICUM
HARNEY COUNTY
16-0092

AUTOPSY PERFORMED:

BY: Clifford C. Nelson, MD 
ON: Thursday, January 28, 2016 – 9:15 a.m.
AT: 13309 SE 84th Avenue, Suite 100, Clackamas, Oregon 97015

CAUSE OF DEATH: GUNSHOT WOUNDS OF THE BACK, ABDOMEN
AND CHEST

MANNER OF DEATH: HOMICIDE

SUMMARY OF AUTOPSY FINDINGS:

- I. GUNSHOT WOUND OF THE LEFT SHOULDER:
 - A. Indeterminate-range gunshot entrance wound of the posterior left shoulder.
 - B. Back-to-front, left-to-right gunshot wound path perforating the deltoid muscle.
 - C. Gunshot exit defect of the anterior left shoulder.

- II. GUNSHOT WOUND OF THE LEFT UPPER BACK AND CHEST:
 - A. Indeterminate-range gunshot entrance wound of the left upper back.
 - B. Back-to-front, right-to-left, slightly downward gunshot wound path with:
 1. Perforating fracture of the posterior left 3rd rib.
 2. Perforation of the upper lobe of the left lung.
 3. Perforating fracture of the anterior left 4th rib.
 - C. Gunshot exit defect above and medial to left nipple.

- III. GUNSHOT WOUND OF THE RIGHT LOWER BACK, ABDOMEN AND CHEST:
 - A. Indeterminate-range gunshot entrance wound of the right lower back.
 - B. Right-to-left, back-to-front, upward gunshot wound path with:
 1. Perforation of the posterior right 10th intercostal space.

OFFICIAL COPY
DO NOT RELEASE WITH YOUR RECORDS
CONTACT MEDICAL EXAMINER FOR PUBLIC RELEASE INFORMATION



2. Laceration of the lower lobe of the right lung.
 3. Perforation of the diaphragm.
 4. Perforation and pulpefaction of the upper right kidney.
 5. Perforation of the hepatic flexure of the colon.
 6. Perforation of the liver.
 7. Perforation of the diaphragm.
 8. Perforation of the pericardial sac.
 9. Perforation of the right ventricle of the heart.
 10. Laceration of the lingula of the left lung.
 11. Perforation of the anterior left 4th intercostal space and fracture of the left 5th rib.
- C. Gunshot exit defect below and medial to the left nipple.
- IV. ABSENCE OF ACUTE BLUNT FORCE TRAUMA.
- V. ABSENCE OF GROSSLY EVIDENT NATURAL DISEASE PROCESSES THAT WOULD HAVE CONTRIBUTED TO THE DEATH.
- VI. OTHER PROCEDURES:
- A. Blood and urine submitted for toxicologic analysis.
 - B. No tissue retained for histology.
 - C. X-rays retained at medical examiner's office.
 - D. Documentary photographs taken by Deschutes County Sheriff's Detective Donny Patterson and Oregon State Police Forensic Scientist Dan Alessio.
 - E. Clothing submitted as evidence to Detective Patterson.
 - F. Personal effects submitted as evidence to Detective Patterson.
 - G. Blood placed on filter paper for possible DNA analysis.

PRESENTATION OF BODY:

The fully clothed body of the subject is first viewed lying on a portable morgue stretcher.

ITEMS ON BODY:

A pair of white metal handcuffs is around the wrists, pulling the arms and hands behind the back.

CLOTHING ON BODY:

1. Brown "Ariat" brand cowboy boots cover the feet.
2. Gray socks cover the feet.
3. A second pair of gray socks cover the feet.
4. "Wrangler" brand blue denim jeans cover the waist, hips and legs. They are appropriately buttoned and zipped. A brown leather belt with brass colored plate-style buckle, which is unfastened, is through the loops of the pants appropriately.
5. Black, cold-proof, full-length thermal underwear cover the legs, hips and waist.
6. White, long legged underwear cover the waist, hips and genitalia.
7. A "Levi" brand blue denim jacket covers the arms and drapes around the back. It is unbuttoned. A defect in the left rear aspect of the jacket corresponds with a bullet hole in the body.
8. A white fleece "Champion" brand vest sweater with black trim covers the arms and drapes around the back. It is unzipped. Defects near the left shoulder and in the left chest correspond with gunshot wounds of the body. Corresponding bullet defects are also found in the right bottom rear and left neck area of the vest.
9. A black snap long-sleeve cotton shirt with burgundy, light brown and white lines covers the arms and drapes around the back. Three holes are in the posterior right rear. One in the left posterior neck, one near the left

shoulder, and another in the left chest correspond with wounds on the body.

10. A black and red trimmed thermal sweat jacket covers the arms, chest and abdomen. It is merino blend by "Paradox" brand. Holes in the left chest, left shoulder, left posterior neck and right back correspond with wounds on the body.

11. A white knit short-sleeve undershirt has defects corresponding with the gunshot wounds on the body.

PERSONAL EFFECTS:

1. In the right front jeans pocket is a red "BIC" lighter and small white metal case.
2. A folding pocket knife and white metal and plastic container holds matches and filters.
3. A pair of dark brown reading glasses is in the shirt pocket.
4. Two "Halls" cough drops are in the right front lower jacket pocket.
5. "Degrees" brand earmuffs are around the left wrist.
6. A white metal "Timex" brand watch with brown leather strap surrounds the left wrist.

EVIDENCE OF MEDICAL THERAPY:

EKG pads are on both iliac crests, the right clavicular region and left axilla.

GENERAL EXTERNAL EXAMINATION:

Received is the unembalmed, well-hydrated, well-nourished, normally developed, relatively thin body of an adult Caucasian male appearing at least 5 years older than the age of 55. When first viewed, the body is in full rigor, and lividity is posterior, fixed and nonblanching. The body is cool to the touch after having been refrigerated. The subject is 67 inches and 167 pounds.

The scalp is shaved bald. The irides are brown. The conjunctivae are free of petechial hemorrhages and the corneas are clear. The nose is midline, externally uninjured, and with a slight amount of blood in the nostrils. The ears are normally formed and set with no blood or debris in the external auditory canals. The earlobes are not creased or pierced. The lining of the mouth and gums is uninjured. The dentition is natural, worn, but in good condition.

The neck is free of palpable masses, and the trachea is midline.

The thorax is normally formed, symmetric and remarkable for gunshot wounds to be described separately.

The abdomen is flat, soft, free of palpable masses and uninjured.

The external genitalia are those of a normally developed, circumcised adult male with bilaterally descended testes and a genital hair pattern appropriate for age and sex.

The arms, hands and fingers are normally formed, symmetric and without traumatic injuries. The fingernails are trimmed 1/8 inch proximal to the tips of the fingers and have no underlying debris. The palms are uninjured and the antecubital fossae are free of perivenous puncture marks or scarring.

The legs, feet and toes are normally formed, symmetric and without traumatic injuries. The toenails are trimmed 1/4 inch proximal to the tips of the toes and have no underlying dirt or debris. The soles are clean and uninjured. On the 3rd left toe dorsally is a 1-1/2 x 1-inch purple and brown contusion with 2 areas of central spacing creating what appears to be the number "8."

The back is normally formed, symmetric and with gunshot entrance wounds to be described separately. The anus and perineum are unremarkable.

SCARS AND TATTOOS:

No surgical or traumatic scars are located. No tattoos are present on the body. What appears to read "2Gas Call" is written in black pen ink on the left palm.

GUNSHOT WOUNDS:

#1 – Gunshot Wound of the Left Shoulder: An indeterminate-range gunshot entrance wound is located on the left shoulder, 58-1/2 inches above the left heel and 9 inches left of posterior midline. The defect consists of a 1/8-inch-diameter hole with crescent shaped, up to 1/4-inch-wide marginal abrasion from 2 to 8 o'clock. Soot, searing and stippling are absent from the surrounding skin or within the depths of this portion of the wound.

The gunshot wound path courses from back to front, left to right and without significant above-to-below deviation. It perforates the left deltoid muscles. The wound path consists of an approximately 1/2-inch-diameter, collapsed hemorrhagic cavity.

A slightly shored gunshot exit defect is located in the anterior left shoulder, 58 inches above the left heel and 6-1/4 inches left of anterior midline. The defect consists of a 1/4-inch-diameter hole with 1/8-inch-wide, near circumferential, irregular shored abrasion. Soot, searing and stippling are absent from the surrounding skin or within the depths of this portion of the wound.

#2 – Gunshot Wound of the Neck and Upper Chest: An indeterminate-range, gunshot entrance wound of the upper left back is located 58-1/8 inches above the left heel and 2-1/2 inches left of posterior midline. The defect consists of a 1/8-inch-diameter hole with 1/8-inch-wide circumferential marginal abrasion.

Soot, searing and stippling are absent from the surrounding skin or within the depths of this portion of the wound.

The gunshot wound path courses from back to front, right to left, and slightly downward. The bullet perforates and fractures the posterior left 3rd rib, perforates the upper lobe of the left lung, and perforates and fractures the left 4th rib. Small to minute fragments of lead and copper are found along the wound path. Approximately 1 liter of liquid and clotted blood is within the left hemithorax.

An irregular, 3/8 x 1/4-inch gunshot exit defect is located above and medial to the left nipple, 50-5/8 inches above the left heel and 3-3/4 inches left of anterior midline. The defect has no surrounding marginal abrasion. No soot, searing or stippling is present on the surrounding skin or within the depths of this portion of the wound. A vertical, 3/4 x 1/8-inch wide superficial abrasion is just lateral to this gunshot exit defect and a 5/8 x 3/8-inch irregular shaped superficial abrasion is located approximately 2 inches from the edge of the exit defect at 2 o'clock.

#3 – Gunshot Wound of the Right Lower Back, Abdomen and Chest: An indeterminate-range gunshot entrance wound of the lateral right lower back is located 44 inches above the right heel, 4-1/2 inches right of posterior midline. The defect consists of a 1/8-inch-diameter hole with up to 3/16-inch-wide marginal abrasion extending from 2 to 8 o'clock. Soot, searing and stippling are absent from the surrounding skin or within the depths of this portion of the wound.

The gunshot wound path courses from back to front, right to left and upward. The bullet perforates the posterior left 10th intercostal space, lacerates the lower lobe of the right lung, perforates the diaphragm, perforates and shreds the upper right kidney, perforates the hepatic flexure of colon, and perforates the liver. The bullet continues by perforating the diaphragm, perforating the pericardial sac, and

perforating the right ventricle of the heart. The bullet then perforates the lingula of the left lung, the anterior left 4th intercostal space, and fractures the left 5th rib. Approximately 1500 mL of liquid and clotted blood is within the right hemithorax. Approximately 300 mL of liquid and clotted blood is within the peritoneal cavity.

An irregular, splitting, gunshot exit defect is approximately 3/8 inch in diameter. It is located 48-1/2 inches above the left heel and 3-1/2 inches left of anterior midline. Soot, searing and stippling are absent from the surrounding skin or within the depths of this portion of the wound. No marginal abrasion is apparent.

GENERAL INTERNAL EXAMINATION:

Body Cavities: Pneumothoraces, the perforated pericardial sac, and the hemoperitoneum have been previously described. The thoracic and abdominal organs maintain their usual anatomic relationships.

Cardiovascular System: The 320 gram, normally formed heart is injured by the gunshot wound as previously described. The heart is covered by moderate overlying epicardial fat. Serial sections through the coronary arteries reveal a right dominant system with no stenosis by atherosclerotic plaque. The cardiac valves are thin, supple, translucent, free of nodularity, and of normal circumference. The homogeneous red-brown myocardium has no focal pallor, softening, hyperemia or scarring. The aorta arises and courses normally through the thorax and abdomen. It is uninjured along its course. No atherosclerotic plaquing is identified, and the ostia of the major branches off the aorta are widely patent.

Respiratory System: The right 580 and left 360 gram lungs have hemorrhage associated with the gunshot wound paths as previously described. The pleural surfaces have moderate anthracotic pigmentation but no adhesions. The airways contain bloody mucus but are free of foreign material, purulence or

masses. The pulmonary arteries course normally and are free of thromboemboli. The sectioned pulmonary parenchyma is free of cysts, masses, abscesses or areas of consolidation.

Gastrointestinal System: The esophagus is lined by an unremarkable beige mucosa without lesions. The stomach contains approximately 800 grams of what appears to be ground meat material and potatoes. The rugal folds of the stomach are covered by an uninjured beige mucosa. External examination of the small bowel and colon reveals no strictures, adhesions, diverticula, masses or injuries. The appendix is present.

Liver, Gallbladder and Pancreas: The 1420 gram liver has a smooth, red-brown surface where not injured but gunshot wounds. The sectioned hepatic parenchyma is free of nodularity, increased fibrosis, cysts or masses.

The thin-walled gallbladder contains approximately 15 mL of bile and no stones.

The beige, lobular pancreas has slight surrounding hemorrhage but no cysts, masses, parenchymal hematomas, abscesses, saponification or calcification.

Spleen: The 110 gram spleen has a wrinkled purple capsule. White pulp is evident upon sectioning.

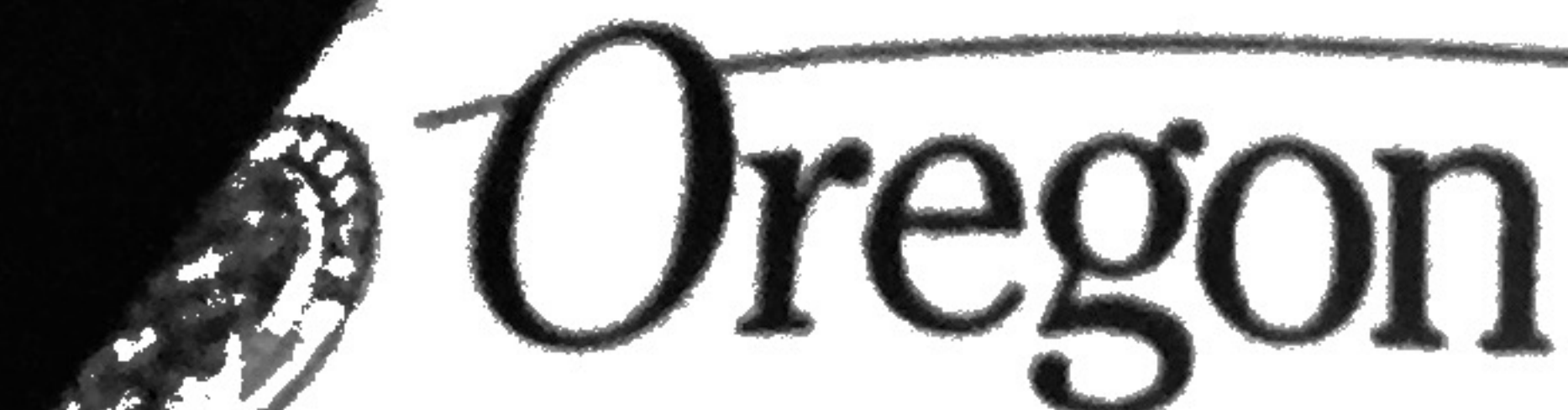Genitourinary System: The right kidney has a shredded upper pole and is 100 grams. The left kidney is 130 grams. Intact capsule of both kidneys is smooth without nodularity or granularity. The pelves are not dilated and the calyces are sharp. The cortices and medulla are distinct. The bladder contains approximately 100 mL of urine. The bladder wall is not thickened or trabeculated. The testes and prostate are not examined.

Endocrine System: The pituitary, thyroid and adrenal glands are in the usual locations and appear of normal size, shape, color and consistency.

Axial Musculoskeletal System: The ribs are fractured by the gunshot wounds as previously described and hemorrhage within the intercostal muscles has also been described.

Neck Contents: The anterior strap muscles of the neck are free of hemorrhage. Thyroid and hyoid cartilages are unfractured. Paracervical and paratracheal soft tissues are uninjured, and the larynx is unremarkable.

Head: Scalp and subgaleal hemorrhage are absent. The bones of the cranial vault are intact and unfractured. Epidural, subdural and subarachnoid hemorrhage does not exist. The normally formed, nonsoftened, nonflattened gyri of the 1600 gram brain are covered by a thin, transparent, glistening pia and arachnoid. Coronal sections through the cerebral hemispheres and serial sections of the brainstem, midbrain and cerebellum reveal no focal lesions. The vessels of the circle of Willis course normally about the base of the brain and are free of atherosclerotic disease or aneurysmal dilatation.



Oregon

Kate Brown, Governor

February 3, 2016

Department of State Police
Forensic Laboratory
13309 SE 84th Ave.
Clackamas, OR 97015
State Medical Examiner
971-673-8200
FAX 971-673-8321

Harney County Medical Examiner's Office
559 W Washington Street
Burns, OR 97720

Attention: CLIFFORD NELSON MD
FINICUM, ROBERT L. (DOD: 1/26/16)
Lab No. 16M-000184
Agency Case 16-0092

Analytical Report

Described below is a summary of the analytical results and/or conclusions of the undersigned analyst concerning the referenced exhibit(s) submitted by your agency and received sealed on January 29, 2016 via Tommy Bottom.

Exhibit 01 - A grey-stoppered femoral blood specimen which is labeled as FINICUM, ROBERT L.

Toxicological examination fails to confirm the presence of controlled substances or common pharmaceuticals.

Refer to other report(s) regarding this case.

This analysis was requested by Clifford C. Nelson, M.D.

Evidence will be returned at the earliest convenience.

Janet L. Schultz, Forensic Scientist

Pursuant to ORS 40.460 (25), I hereby certify that I retrieved this document directly from the computer system maintained and operated by the Oregon Department of State Police and that this document accurately reflects and is a true copy of the information contained in that computer system. In testimony whereof, I have affixed my signature.

OFFICIAL COPY
DO NOT RELEASE WITH YOUR RECORDS
CONTACT MEDICAL EXAMINER FOR PUBLIC RELEASE INFORMATION



February 3, 2016

Department of State Police
Forensic Laboratory
13309 SE 84th Ave.
Clackamas, OR 97015
State Medical Examiner
971-673-8200
FAX 971-673-8321

Harney County Medical Examiner's Office
559 W Washington Street
Burns, OR 97720

Attention: CLIFFORD NELSON MD
FINICUM, ROBERT L. (DOD: 1/26/16)
Lab No. 16M-000184
Agency Case 16-0092

Analytical Report

Described below is a summary of the analytical results and/or conclusions of the undersigned analyst concerning the referenced exhibit(s) submitted by your agency and received sealed on January 29, 2016 via Tommy Bottom.

Exhibit 02 - A red-stoppered urine specimen which is labeled as FINICUM, ROBERT L.

Toxicological examination indicates the presence of the following; however, these results are not confirmed:

- Ibuprofen

Toxicological examination also indicates the presence of 7-Hydroxycoumarin; however, this result is not confirmed.

This analysis was requested by Clifford C. Nelson, M.D.

Evidence will be returned at the earliest convenience.

Janet L. Schultz, Forensic Scientist

Pursuant to ORS 40.460 (25), I hereby certify that I retrieved this document directly from the computer system maintained and operated by the Oregon Department of State Police and that this document accurately reflects and is a true copy of the information contained in that computer system. In testimony whereof, I have affixed my signature.

Oregon

Kate Brown, Governor

January 2, 2016

Department of State Police
Forensic Laboratory
13309 SE 84th Ave.
Clackamas, OR 97015
State Medical Examiner
971-673-8200
FAX 971-673-8321

Harney County Medical Examiner's Office
559 W Washington Street
Burns, OR 97720

Attention: **CLIFFORD NELSON MD**
FINICUM, ROBERT L. (DOD: 1/26/16)
Lab No. 16M-000184
Agency Case 16-0092

Analytical Report

Described below is a summary of the analytical results and/or conclusions of the undersigned analyst concerning the referenced exhibit(s) submitted by your agency and received sealed on January 29, 2016 via Tommy Bottom.

Exhibit 01 - A grey-stoppered femoral blood specimen which is labeled as FINICUM, ROBERT L.

Alcohol/volatiles analysis confirms:

- Ethanol Not Detected
- Acetone Not Detected

This analysis was requested by Clifford C. Nelson, M.D.

Evidence will be returned at the earliest convenience.

Shane Bessett

Shane A. Bessett, Forensic Scientist

Pursuant to ORS 40.460 (25), I hereby certify that I retrieved this document directly from the computer system maintained and operated by the Oregon Department of State Police and that this document accurately reflects and is a true copy of the information contained in that computer system. In testimony whereof, I have affixed my signature.